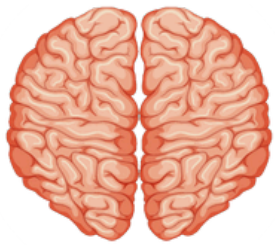
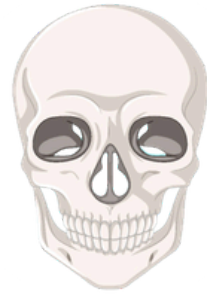
Anatomy of the Human Body



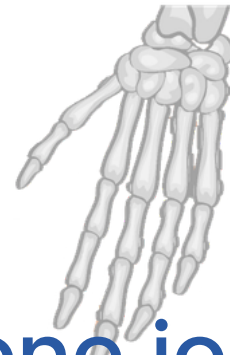
Brain



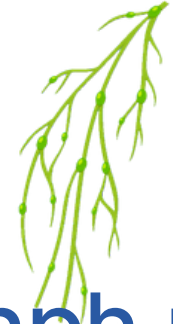Skull




Muscle



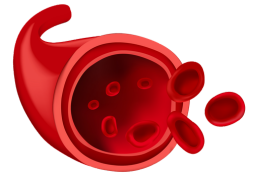Bone joint



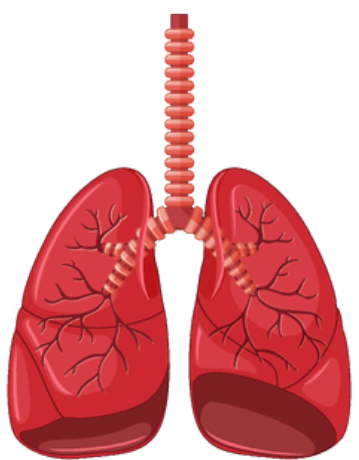
Nymph nodes



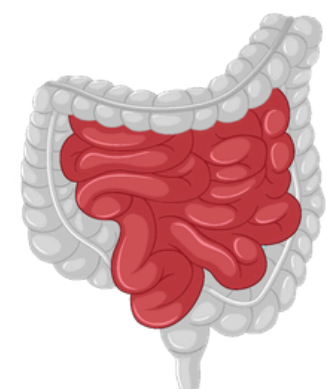
Oesophagus



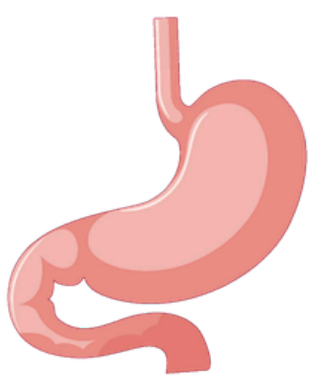Blood vessels



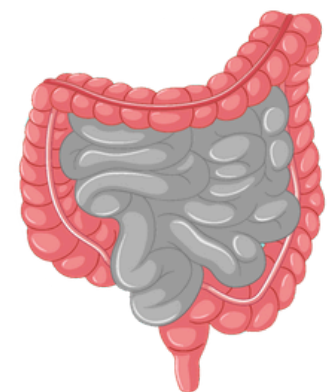
Lungs



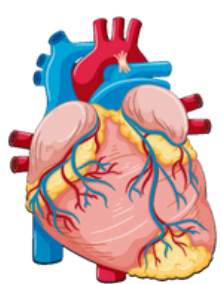
Small intestine



Stomach



Large intestine



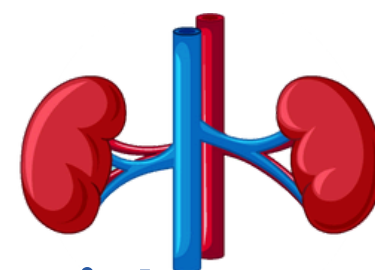
Heart



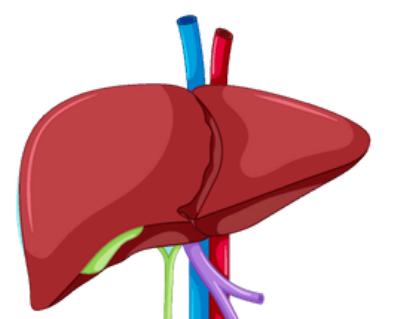
Bladder



Nerve



Kidneys



Liver

